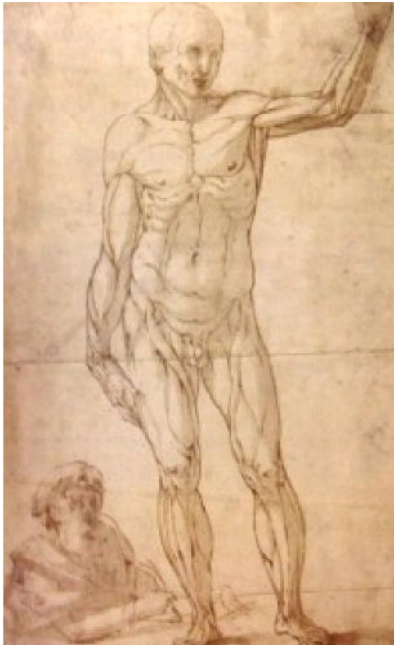

L'épaule du Lundi et si c'était une rupture du supra- épineux

O.Courage /J.Matsoukis

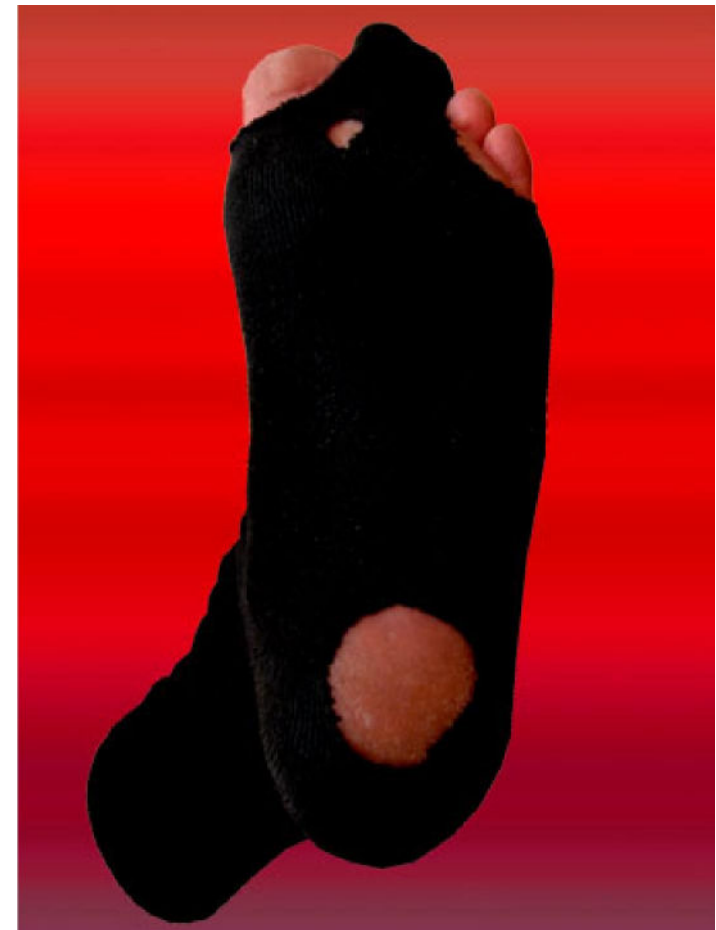


Les sportifs déchirés & les vieux usés

« la cinquantaine »

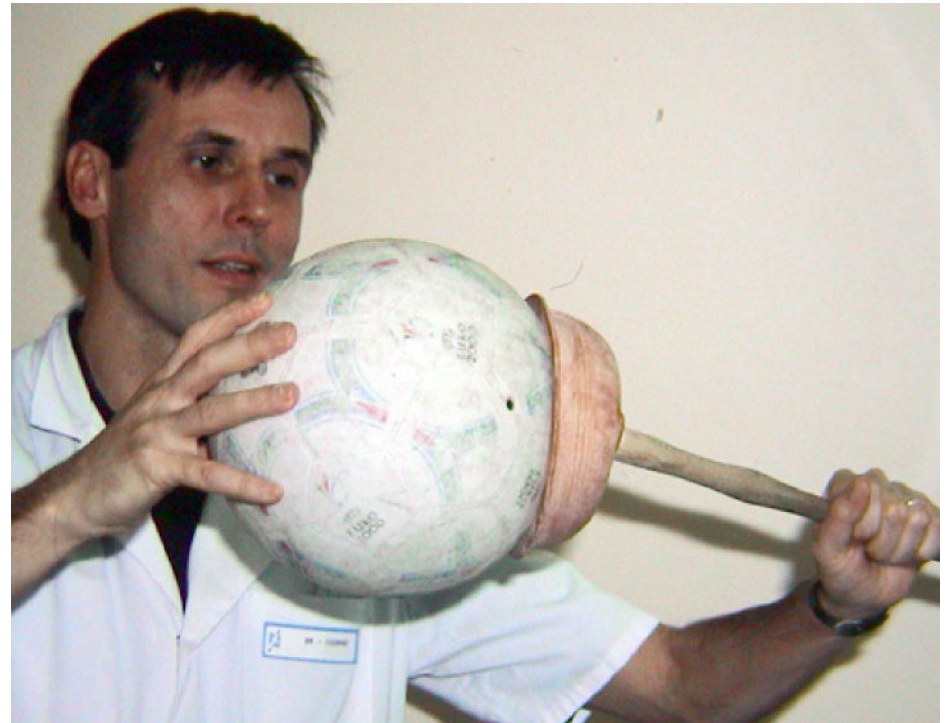

20%

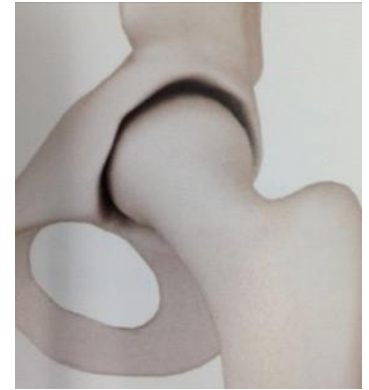

Rappel anatomique

- Mobilité
- Stabilité



Anatomie



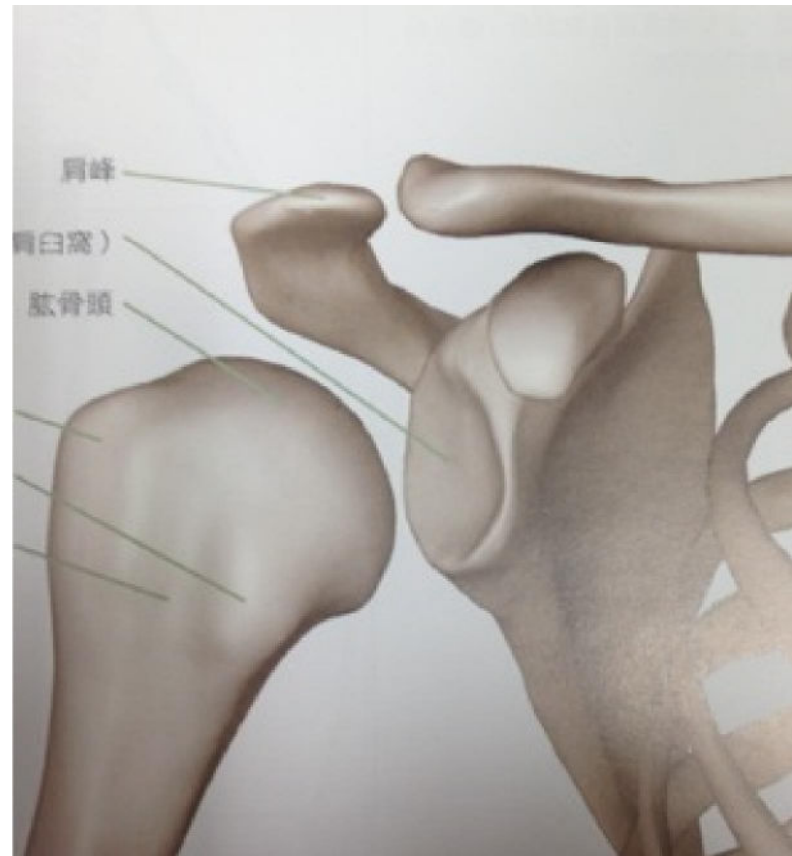- Omoplate
 - Glène
 - Acromion
 - Coracoïde

Tête

Tubérosité

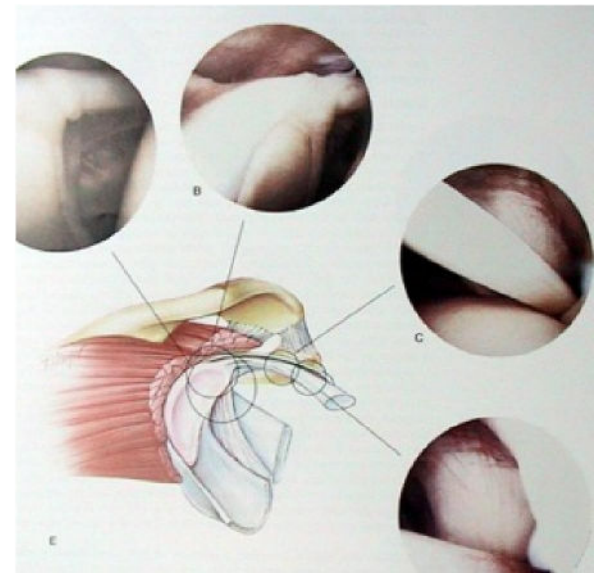
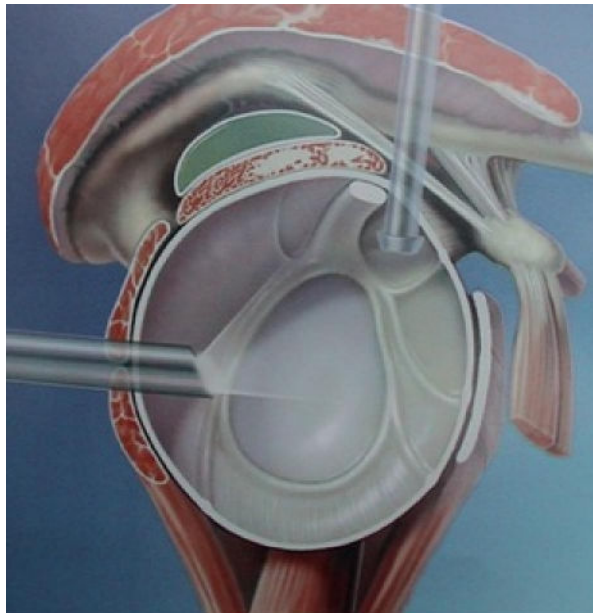
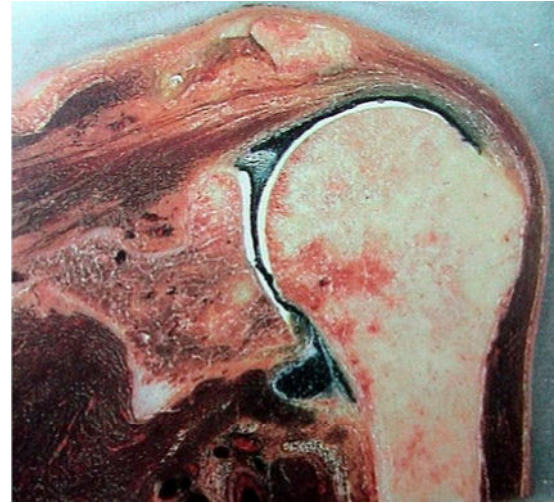
Faible moment

Zone d'insertion



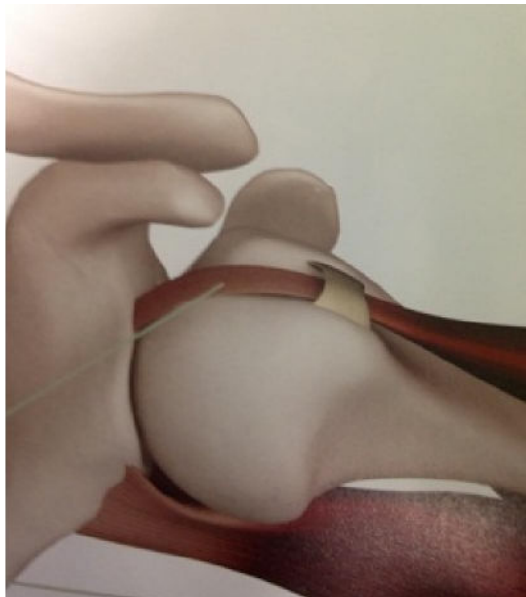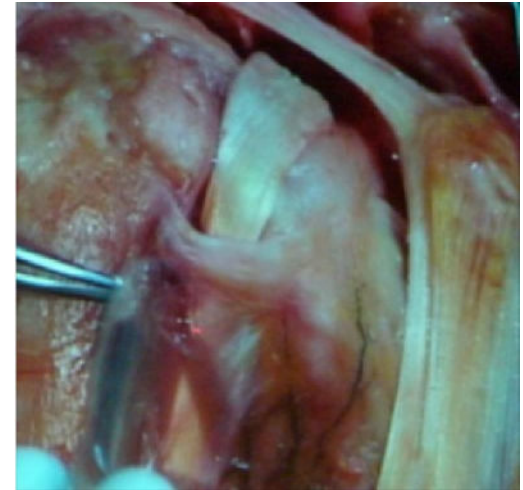
Les moyens d'unions articulaires

- Capsule
- Bourrelet
- biceps



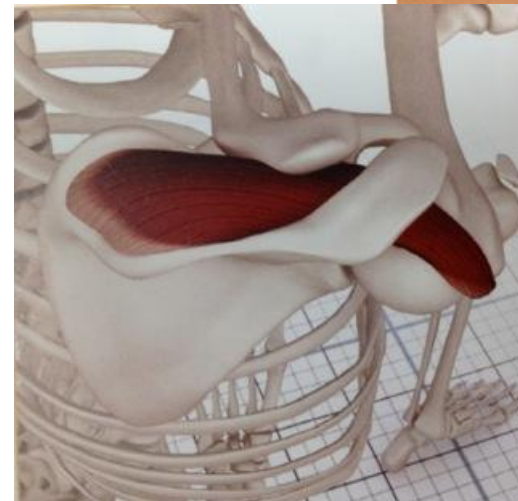
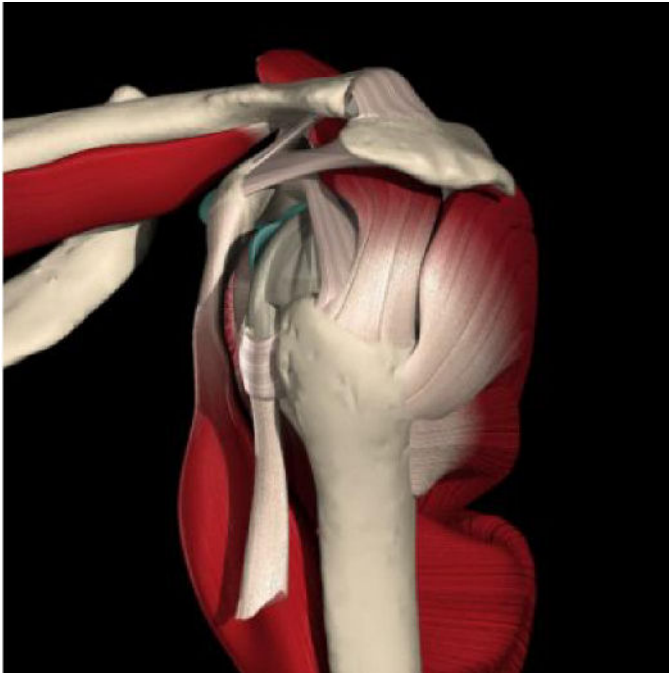
Biceps intra-articulaire

- Rail
- Guide et maintient l'humérus




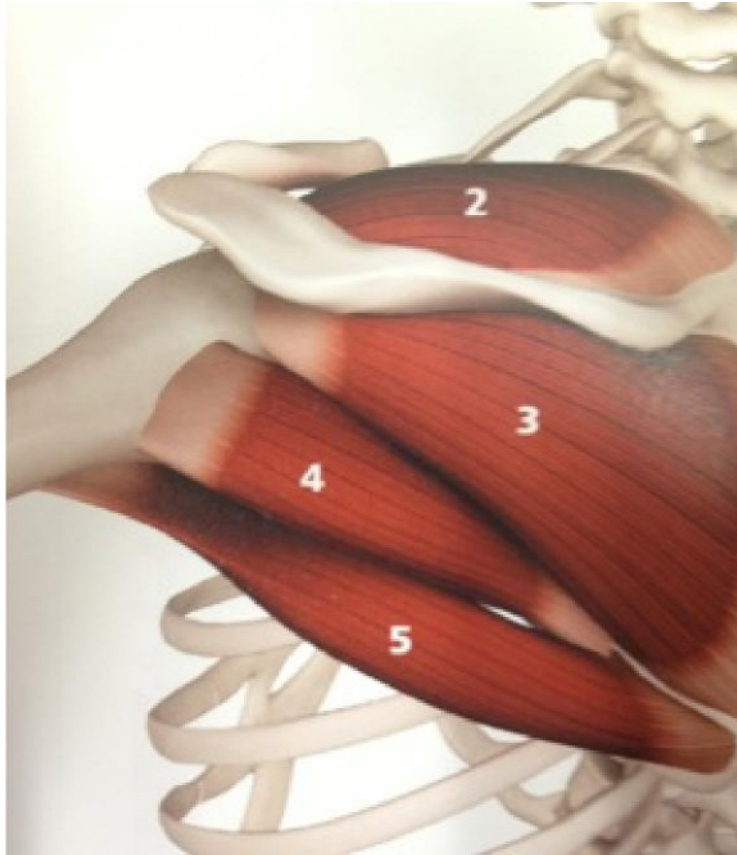
Les muscles & le tennis

- Le service
- Le supra-épineux



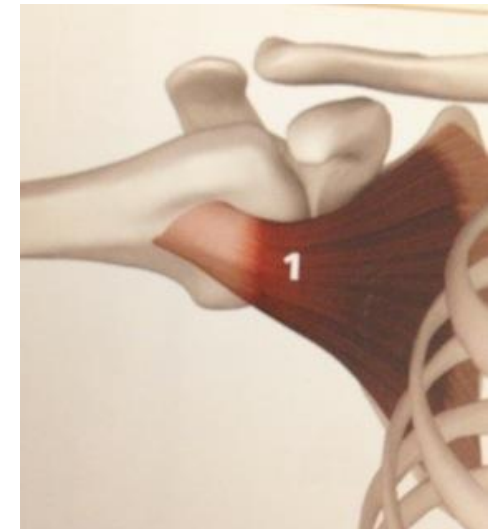
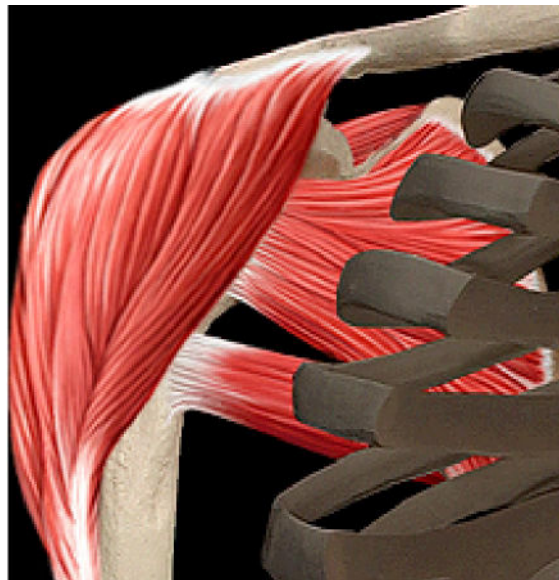
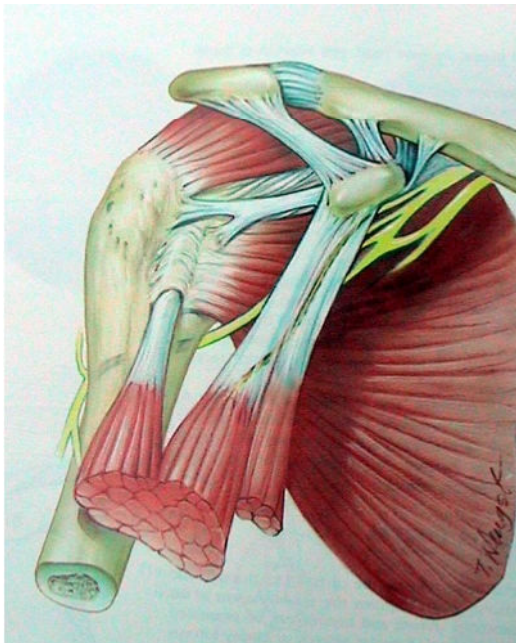
Rotation externe = le revers

- Infra-épineux



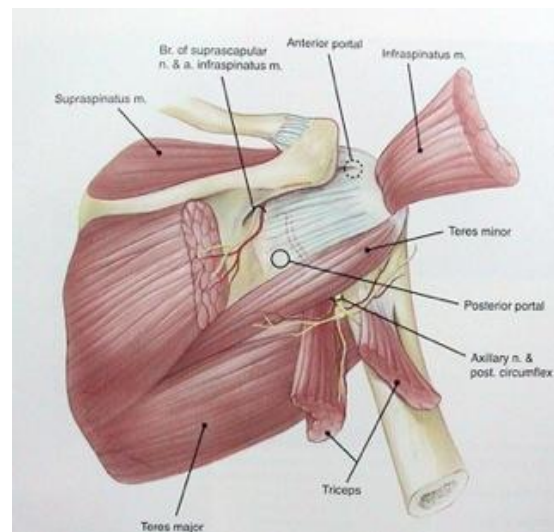
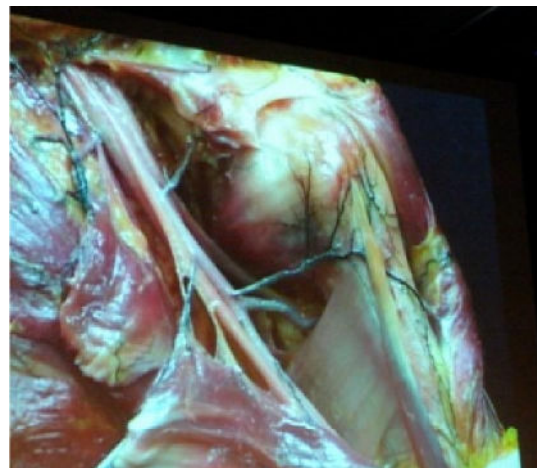
RI : le coup droit

- Le sous- scapulaire
 - Le biceps



Nerf & artères

- Dangers chirurgicaux
- Parfois pathologie
 - Rare
 - Compression



Les signes cliniques

